

HYPODONTIA OF THE UPPER LATERAL INCISORS – A THERAPEUTIC APPROACH AND FACTORS, WHICH HAVE DETERMINED IT (A CLINICAL CASE)

Vera Krumova, I. Yoncheva*

Department of Orthodontics,

*Department of Prosthetic Dentistry,

Faculty of Dental Medicine, Medical University – Sofia, Bulgaria

SUMMARY:

A clinical case of hypodontia of the upper lateral incisors, wedge-shaped canines, microdontia of premolars, diastemata and tremata in the maxilla and mandible is presented. Complex orthodontic-prosthetic treatment has been performed.

Key words: Hypodontia, orthodontic-prosthetic treatment.

Hypodontia is identified as a phylogenetic reduction of teeth number more often affecting the permanent than deciduous dentition. The studies of several authors have reported that the upper lateral incisors are most frequently affected by hypodontia, followed by the upper and lower second premolars (1, 2, 3, 5, 6). From genetic point of view, hypodontia is determined as an autosomal-dominant ectodermal dysplasia.

The functional and aesthetic changes caused by hypodontia impose the necessity of finding a therapeutic approach of shaping the permanent dentition in a way that normal occlusal relationships and improved aesthetics could be achieved.

The reduced number of lateral incisors is of particular significance for aesthetics. In most cases, the necessity of performing orthodontic-prosthetic treatment is a basic requirement, especially for the patients combining hypodontia with changes in the shape and size of available teeth and dental-jaw discrepancy resulting in diastema and a number of tremata. These morphological changes in the dentition are the most common patient's motive for undertaking orthodontic treatment. However, the normal occlusal relationships and aesthetics are not always achievable through orthodontic treatment only. Frequently, the facial soft tissue and musculature tonus depends on dental arch shape and size. These problems solution is an essential part of the orthodontist's creative objective. The presented case is an example of the necessity of a complex orthodontic-prosthetic approach in solving this type of clinical situations. Clinician's conformity with patient's

requirements provided they are reasonable enough and within the limits of clinician's final diagnosis is of importance.

The patient M. D. aged 16 years manifested hypodontia of the upper lateral incisors, microdontia of premolars, wedge-shaped canines, diastemata and a number of tremata in both jaws (**fig. 1** and **fig. 2**).

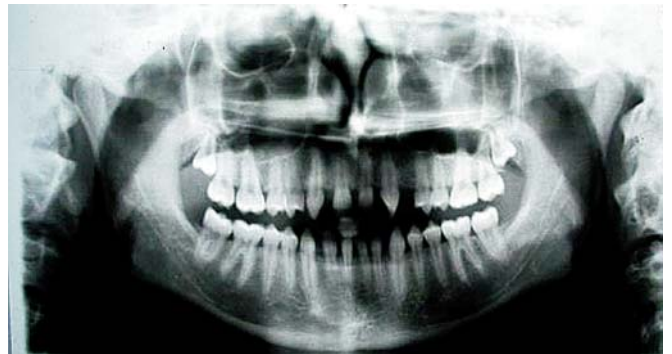

Fig. 1. Pretreatment orthopantomogram

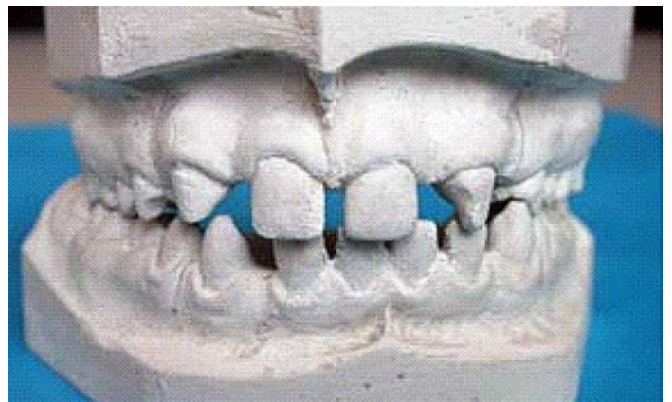


Fig. 2. Pretreatment plaster dental casts

On the background of reduced morphologic structure of her dentition, the patient displayed wide and oval face, which would not harmonize the formation of a small dental arch missing diastemata and tremata, achieved after the preplanned lateral incisor medialization. Following orthodontic preparation, the available beneficial anatomic preconditions for implantation-prosthetic treatment were not realized because of the patient's categorical refusal.

This imposed finding out of another approach associated with redistribution of the interdental space and prosthetic bridge planning.

The mandible underwent no orthodontic treatment for two reasons: 1) available normal occlusion relationships of the second premolars and molars and 2) the patient's refusal to lower anterior teeth size correction by various prostheses such as plastic crown-, facet- or crown-sleeve restorations.

During the orthodontic treatment performed through a fixed technique, the spaces between 11, 13, 14 and 21, 23, 24 were redistributed in a way creating enough space for the lateral incisors, conformable with the mesiodistal diameter and position of the first incisors.

During the replacement of canines, their derotation was required for changing of their radices position and stability in the future construction. The orthodontic treatment has continued for 6 months (**fig. 3, 4 and 5**).

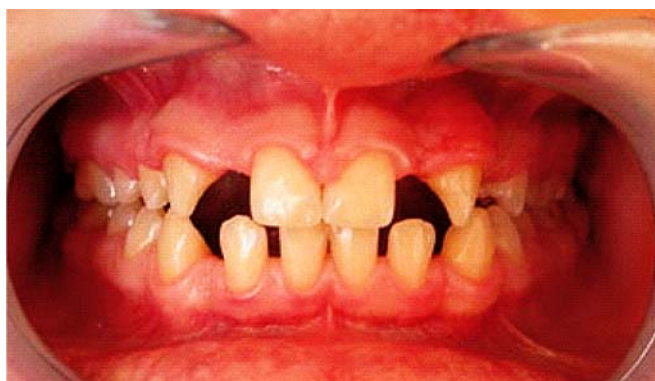
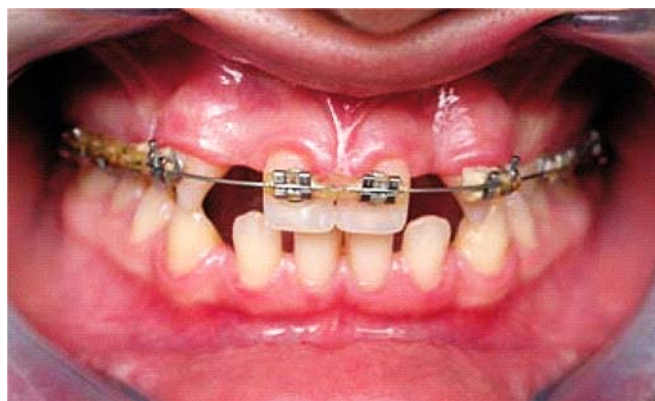
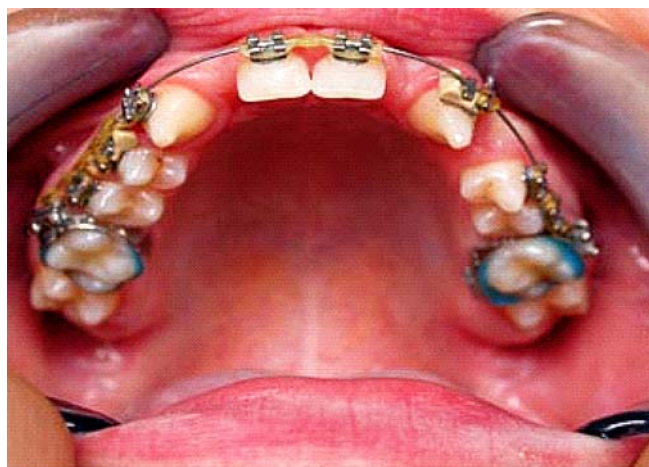Fig. 3, 4 and 5. Completed orthodontic treatment

After the obtainment of the desired result, a stabilization period, during which a retention plate – space-keeper has to be worn, was provided (**fig. 6**).

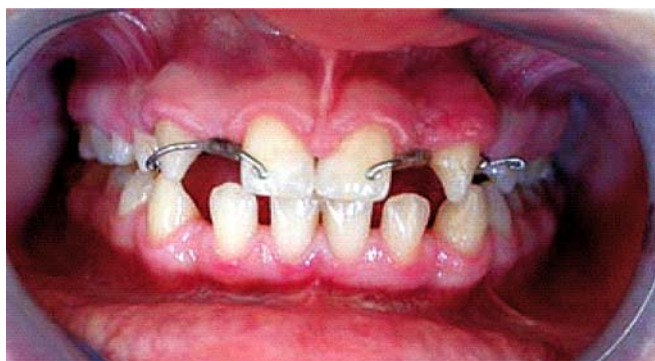

Fig. 6. The retention plate

The retention plate was immediately adjusted after bracket removal, thus avoiding disturbance of the achieved occlusion. This adaptation period was necessary for curing the mucosal hyperemia round the teeth undergone replacement before the manufacturing of temporary restorations. The patient was motivated to wear permanently the retention plate including the periods of feeding, for the undesired relapse preceding the manufacturing of temporary restorations could be avoided. Anti-inflammatory solutions for treating hyperemia and measures for excellent oral hygiene maintenance were administered.

Because of the patient age (16 years), a decision for prosthetic treatment through two bridges on teeth 14, 13 and 23, 24 as abutments, was taken. Thus, the placement of an eight unit bridge including the normally shaped and sized central incisors was avoided (**fig. 4 and 8**).

After achieving control over the inflammatory process, the abutments were prepared and the temporary constructions adjusted within a single clinical phase (**fig. 7**).

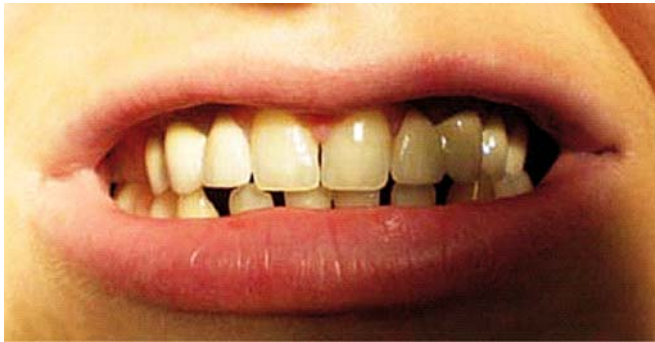

Fig. 7. Temporary prosthetic constructions

The grinding was carefully performed in a way taking off a minimal amount of hard tooth tissues, so the teeth vitality could be preserved. The treatment was completed with porcelain-fused-to-metal restorative constructions (fig. 8 and 9).

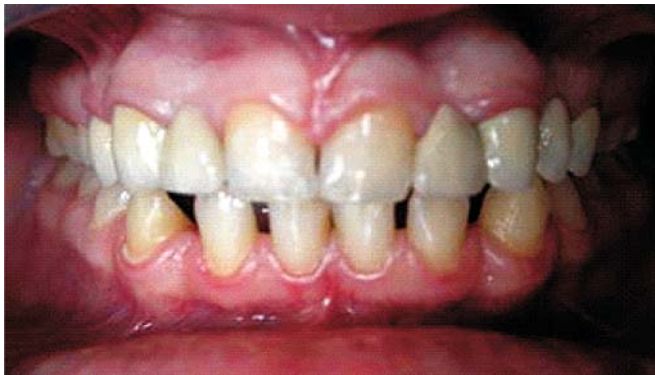

Fig. 8. Final restorative constructions

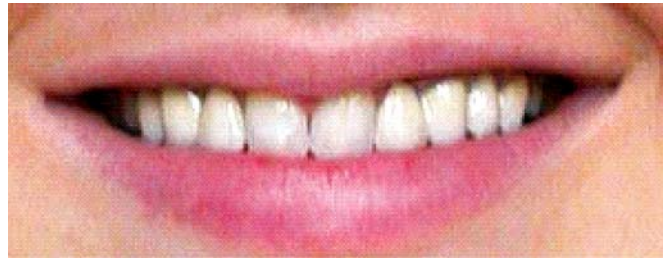

Fig. 9. Completed orthodontic-prosthetic treatment

The adhering to all contiguous stages of treatment as well as the synchronization of both clinicians and patient's participation in the treatment process was essential for avoiding of a relapse.

The presented case is an evidence for the individual approach needed in cases of complex treatment. Besides the clinician's leading role, the individual patient requirements within reasonable limits and in correspondence with clinician's final diagnosis are of importance.

The used tooth hard tissue-sparing therapy allows the replacement of restorative constructions after a continuous medico-biological period.

The basic approach in the complex treatment of adolescents requires the avoidance of large prosthetic constructions, which could restrain jaw development and growth. In view of the chronological age, this period is too early for the placement of a fixed prosthesis. In hypodontia cases, the alternative approaches such as orthodontic, combined orthodontic-prosthetic, prosthetic or implantation-prosthetic treatment, depend on dentition individual characteristics and patient preferences in conformity with biological conditions predetermined mainly by the clinician.

REFERENCES

1. Albrmauir, S. An investigation on heredity and a treatment approach in children with hypodontia. Thesis. Sofia, Faculty of Dental Medicine, MU, 2001, 9 p.
2. Cunha, RF, Delbem AC, Hirata E, Toyota E. Hypodontia in primary dentition: a case report. *J Clin Pediatr Dent*, 1999 Summer; 23 (4):361–3.
3. Dausch-Neumann, D. Die Versorgung von Zahnluücken bei Kindern u. Jugendlichen (eine interdisziplinäres Problem). *Z Stomatol*, 1987; 84:111–120.
4. Gesheva, N. On the issue of hypodontia and its impact on jaw-facial system. Dissertation. Sofia, MU, 1965, 163p.)
5. Ith-Hanser, K, Kjaer I. Persistence of deciduous molars in subjects with agenesis of the second premolars. *Eur J Orthod*, 2000 June; 22 (3):239–43.
6. Mamopoulou, A, Hagg U, Schroder U, Hansen K. Agenesis of mandibular second premolars. Spontaneous space closure after extraction therapy: a 4-year follow-up. *Eur J Orthod*, 1996 Dec; 18 (6):589–600.
7. Shapira, Y, Lubit E, Kuftinec MM. Hypodontia in children with various types of clefts. *Angle Orthod*, 2000 Feb; 70 (1):16–21.
8. Valderhang, J. A 15-year clinical evaluation of fixed prosthodontics. *Acta Odontol Scand*, 1991; 49:35–40.

Address for correspondence:

Dr Vera Krumova, PhD
 Department of Orthodontics, Faculty of Dental Medicine
 1, St. G. Sofiyski Blvd., 14 31 Sofia
 Phone: +359/888 215 791;
 E-mail: krumovav@abv.bg