

SNEDDON'S SYNDROME

Valentin Valtchev¹, Virginia Simeonova², Dimitar Gospodinov¹, Ivelina Yordanova¹, Valentina Dimitrova¹, Verka Pavlova¹, Emiliana Konova⁴, S. Popovska³, Boyko Stamenov²

¹Department of Dermatology and Venereology, ²Department of Neurology, ³Department of General and Clinical Pathology, ⁴Department of Immunology, Medical University – Pleven, Bulgaria

ABSTRACT

Sneddon's syndrome is usually characterized by the association of an ischemic cerebrovascular disease and a widespread livedo reticularis. The incidence of Sneddon syndrome is 4/1000 000. We present 42-year-old woman with livedo reticularis, recurrence ischaemic cerebrovascular accidents, two repetitive miscarriages and positive anti-2GPI antibodies. Skin biopsy specimens reveal inflammatory changes of small- to medium-sized arteries and subendothelial proliferation and fibrosis. The diagnosis Sneddon syndrome is confirmed by skin biopsy, and MR evidence.

We suggest that anti-2GPI antibodies may be pathophysiologically related to the clinical manifestation observed in some patients with Sneddon syndrome.

Key words: Sneddon syndrome, livedo reticularis, ischemic cerebrovascular disease.

INTRODUCTION

Sneddon's syndrome is characterized by livedo reticularis associated with cerebrovascular disease. The condition affects small to medium sized arteries of the dermis-subcutis border. The process begins as an endothelial inflammation followed by occlusion, fibrosis and atrophy of the vessels. Antiphospholipid antibodies were found in some patients with Sneddon's syndrome. The disorder has a slow and progressive clinical course. No effective drug therapy is available.

CASE REPORT

We report a case of Sneddon's syndrome in a 42 year-old woman. She suffered from cerebrovascular accident presented by double vision and lost of consciousness 5 years previously. Because of that she has been treated in the Department of Neurology. In May 2007 a recurrence of her neurological complaints occurred, expressed by dizziness, vomiting, ataxic walking, numbness and muscular debility of the left lower extremity. From medical history she had myocardial infarction three years ago and two repetitive miscarriages. The patient has been suffering from high blood

pressure and migraine for 10 years. She has been having persistent cutaneous lesions on the upper and lower extremities and trunk for the last 20 years.

At physical examination, a slight elevation in pressure levels (150 x 80mm Hg), III degree obesity and slight edema of the lower limbs were found. The neurological examination revealed ataxic walk. Romberg reflex was negative (-) and Babinski was positive (+) in right. The ophthalmologic examination demonstrated an initial angiosclerosis. The dermatological examination showed erythematous violaceous lesions with a reticular pattern, localized in the arms, trunk (Figure 1) thighs and knees (Figure 2, Figure 3). The following exams in the laboratorial evaluation were normal or negative: blood count (including platelet count), glycemia, sodium, potassium, urea, creatinine, creatinine clearance, transaminases, alkaline phosphatase, bilirubin, amylase, holesterol, triglycerides, PT (prothrombin time), VDRL (venereal disease research laboratory) urinary sediment and anticardiolipin antibodies. Anti- β 2GPI antibody was positive (+).

Regarding the image exams abdomen ultrasound scan was normal. Computerized tomography (CT) of the skull revealed pallium atrophy. The Magnetic nuclear resonance (MNR) of the brain demonstrated old and chronic ischemic areas (Figure 4.1; Figure 4.2). The electrocardiogram revealed evidence for a postinfarction cicatrix.

The immunohistochemical examination with CD 34 of two skin biopsies from the livedo lesions revealed endothelial proliferation and obliteration of the small and middle arteries (Figures 5, 6). The diagnosis of Sneddon syndrome in our patient was made on the basis of anamnesis, clinical features, skin biopsy and MNR. Therapeutics was instituted with 100 mg aspirin (acetylsalicylic acid) once a day. The systemic arterial hypertension was controlled.

DISCUSSION

In 1965, Ian Sneddon was the first author to establish a relationship between livedo reticularis and vascular neurological manifestations in six patients, thereby describing the syndrome that today takes his name (6, 8).

Sneddon's syndrome is a rare clinical entity of unknown etiology characterized by the association of livedo reticularis and cerebrovascular lesions (6,10,12). It can also affect other internal organs (kidneys, heart, eyes and peripheral nerves) and in many cases there is concomitant systemic arterial hypertension (8, 9,10,12). It predominates among young women although the mean age group at the moment of diagnosis is in the fifth decade (8,9,12). The disease has a slow and progressive clinical course that can lead to disability or death, due to neurological problems or associated complications (11, 12). There is no treatment that has been recognized as effective. Livedo reticularis is characterized by persistent lesions with a cyanotic coloration, which are not influenced by temperature. (8) They are distributed in the form of an irregular network appearing in general in the trunk (gluteal region and inferior part of the back) from where it extends towards the extremities (along the thighs and dorsal surface of the arms). Livedo usually precedes the onset of the neurological picture, sometimes for several decades and can intensify in the acute phase of a neurological complication (8,12). The neurological picture as described by Sneddon consists of hemiplegia, aphasia, epilepsy, hemianopsia and hemianesthesia (5, 10). Since then, several other manifestations have been reported: migraine symptoms episodes of transitory cerebral ischemia, paresthesia, convulsions, vertigos, visual symptoms -scintillant scotomata, double vision (8,12). Manifestations related to the cardiovascular system include mild systemic arterial hypertension (occurring in 60 to 80% of the cases and considered by some authors to be part of the syndrome. There is no specific biological marker for Sneddon's syndrome. Routine laboratory exams are usually normal (8, 10). Immunological studies are generally negative. Anti-DNA, anti-SSA, anti-SSB, anti-Sm and anti-RNP antibodies are never found (8). Rheumatoid factor is also negative. However, occasionally the presence of antinuclear antibodies, cryoglobulins, antiphospholipid antibodies, anticardiolipin, lupus anticoagulant or anti-β2GPI antibodies can be detected (1, 6, 8, 9). Imaging of the central nervous system can be made by CT or MNR (2, 8,12). CT and MNR are techniques with equal effectiveness in the detection of major and medium sized infarcts. However, MNR is more sensitive for the precocious detection of encephalic lesions and frequently reveals more extensive and numerous lesions than would be possible to see by CT (12).

In the case reported here, anti-β2GPI antibody were positive (+). CT and MNR showed the presence of ischemic cerebral lesions. Histopathological study revealed that the disease affects small and medium arteries, located in the profound dermis and superior band of the subcutaneous cellular tissue (7). No involvement of other organs was detected.

The etiology of the Sneddon's syndrome is unknown

however, some associated factors that may participate in its etiopathogenesis or even aggravate its clinical course have been reported in the literature (6, 12). There is evidence that female sex hormones could play a role. Systemic arterial hypertension is correlated to the progression of the damage to the central nervous system (8,9). The participation of antiphospholipid antibodies is also controversial (1,3,4) since there are reports of cases in which these antibodies were detected (1,4, 6, 9) as well as others in which they were not (5, 12). Thus, the relationship between Sneddon's syndrome and the Antiphospholipid antibody syndrome is not yet well established (1,3,6,9). It is also necessary to consider that classic manifestations of the latter, such as recurrent thrombosis of the veins or major arteries, thrombocytopenia and a history of spontaneous abortions, have not been reported in Sneddon's syndrome (8,9,12). Sneddon's syndrome is not a homogeneous disease entity. Patients should be classified as "primary Sneddon's syndrome" if no aetiological factor can be detected (4). On clinical grounds this form differs from several varieties of "Secondary Sneddon's syndrome" which occur mainly as part of an autoimmune disorder. When Sneddon's syndrome is associated with positive anticardiolipin antibodies it could be regarded as Antiphospholipid syndrome and fall into this category of nosological entity (4).

CONCLUSION:

We report a case of Sneddon's Syndrome, associated with an Antiphospholipid syndrome, presented by livedo reticularis, cerebrovascular disease, high blood pressure, migraine, two miscarriages and positive (+)anti-β2GPI antibody. In the reported case the livedo reticularis precedes the onset of the neurological picture for several decades.

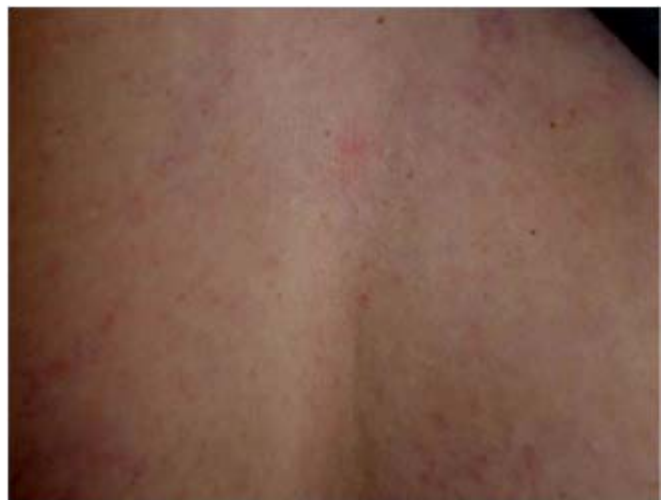

Figure 1.

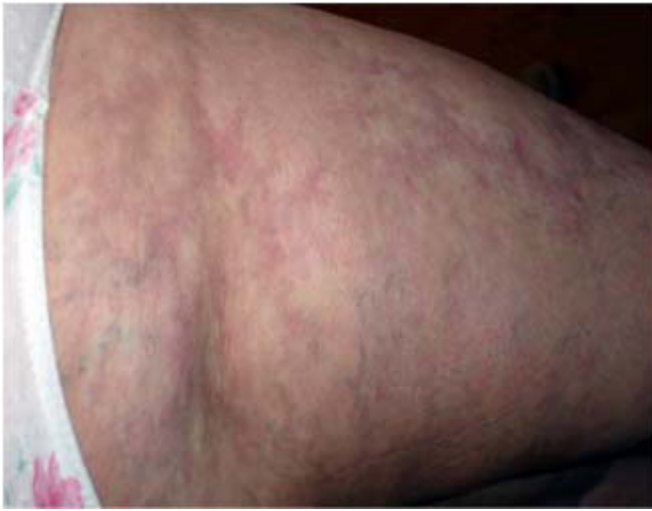

Figure 2.

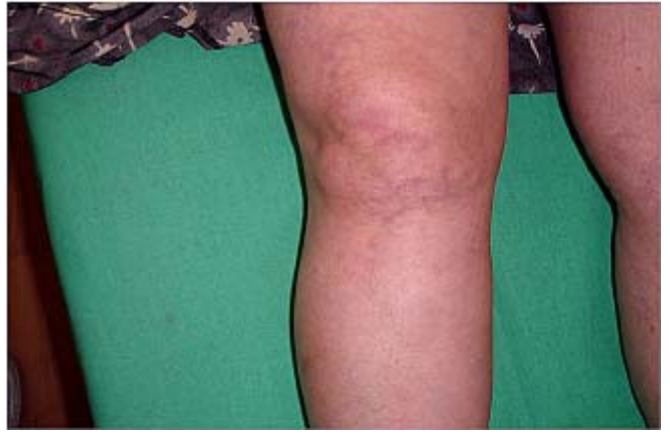

Figure 3.

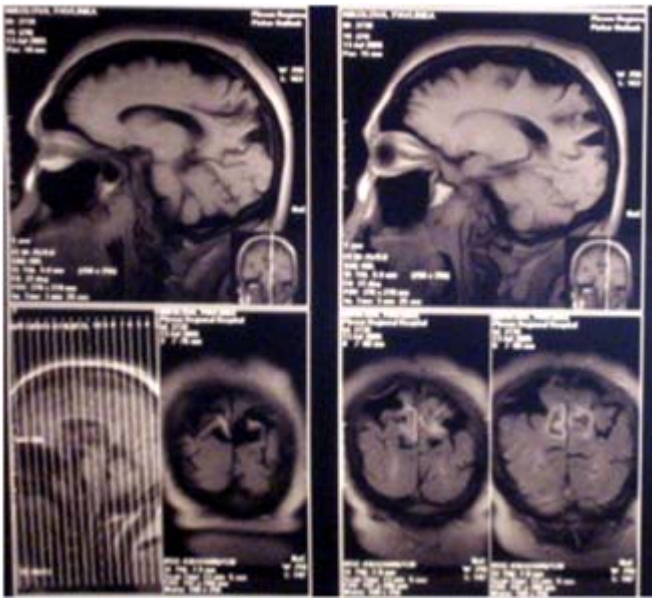


Figure 4-1.

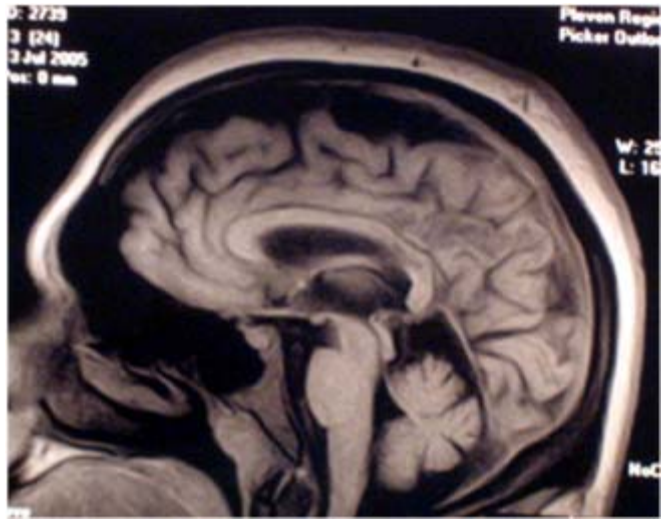


Figure 4-2.

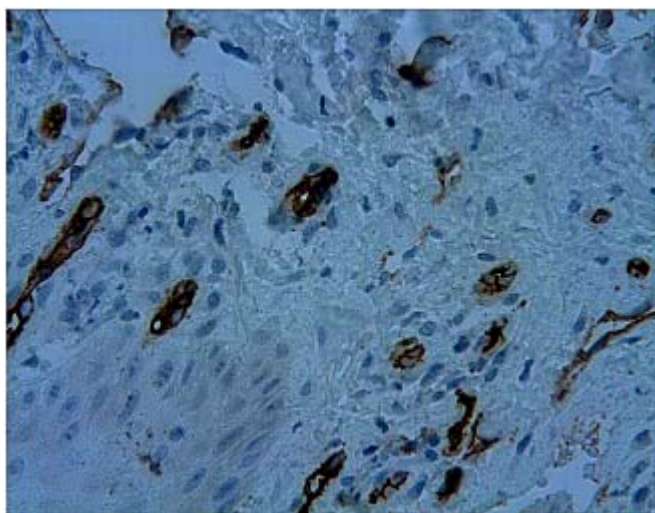


Figure 5.

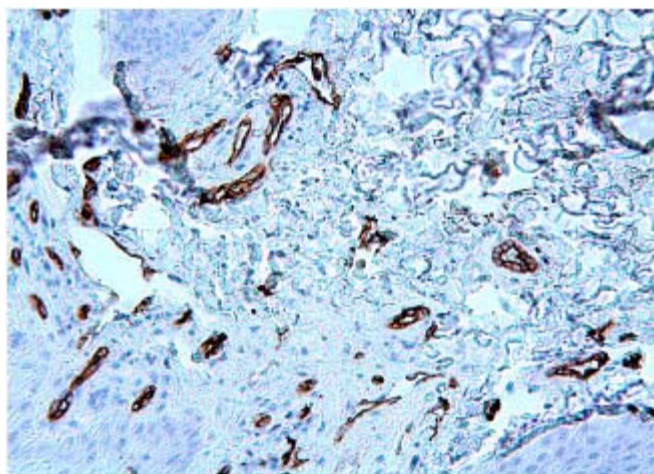


Figure 6.

REFERENCES:

1. Baleva M, Chauchev A, Dikova C et al. Sneddon syndrome: echocardiographic, neurological and immunological findings. *Stroke* 1995;26(7):1303-4.
2. Blom RJ. Sneddon syndrome: CT, arteriography and MR imaging. *J Comput Assist Tomogr* 1989;13(1):119-22.
3. Fine RM. Sneddon syndrome: a diagnosis you do not want to miss. *Int J Dermatol* 1990;29(7):479-80.
4. Gancheva M., Tsankov N. Livedo reticularis and cerebrovascular accident (Sneddon's Syndrome) as a clinical expression of antiphospholipid syndrome. *J EUR Acad Dermatol Venereol* 1999; 12(2): 157-160.
5. Geschwind DH, FitzPatrick M, Mischel PS, Cummings JL. Sneddon's syndrome is a thrombotic vasculopathy: neuropathologic and neuroradiologic evidence. *Neurology* 1995;45(3 Pt 1):557-60.
6. Levine SR, Langer SL, Alberts JW, Welch KMA. Sneddon's syndrome: an antiphospholipid antibody syndrome? *Neurology* 1988;38(5):798-800.
7. Marsch WC, Muckelmann R. Generalized racemosa livedo with cerebrovascular lesions (Sneddon syndrome): an occlusive arteriopathy due to proliferation and migration of medial smooth muscle cells. *Br J Dermatol* 1995;112(6):703-8.
8. Richard MA, Grob JJ, Durand JM, Noe C, Basseres N, Bonerandi JJ. Le syndrome de Sneddon. *Ann Dermatol Venereol* 1994;121(4):331-7.
9. Sempere AP, Martinez B, Bermejo F, Tahoces MF, Cabello A. Sneddon's syndrome: its clinical characteristics and etiopathogenic factors. *Rev Clin Esp* 1992;191(1):3-7.
10. Sneddon IB. Cerebro-vascular lesions and livedo reticularis. *Br J Dermatol* 1965;77:180-5.
11. Zelger B, Sepp N, Schmid KW, Hintner H, Klein G, Fritsch PO. Life history of cutaneous vascular lesions in Sneddon's syndrome. *Hum Pathol* 1992;23(6):668-75.
12. Zelger B, Sepp N, Stockhammer G et al. Sneddon's syndrome. A long term follow-up of 21 patients. *Arch Dermatol* 1993;129(4):437-47.

Address for correspondence:

Valentin Ivanov Valtchev
 Department of Dermatology and Venereology, Medical University of Pleven
 91, Gen. Vladimir Vazov str., 5800 Pleven, Bulgaria
 E-mail: drviv@abv.bg