

## DESQUAMATIVE GINGIVITIS AS A SYMPTOM OF DIFFERENT MUCOCUTANEOUS DISORDERS

Christina Popova, Velitchka Doseva, Kamen Kotsilkov  
 Department of Periodontology,  
 Faculty of Dental Medicine, Medical University - Sofia, Bulgaria

### ABSTRACT

Desquamative gingivitis is a descriptive term of nonspecific clinical expression in the gingiva (redness, burning, erosion, pain) of several dermato-mucous disorders - cicatricial and bullous pemphigoid, pemphigus vulgaris, erosive lichen planus, erythema multiforme, psoriasis, and allergy. These diseases often present with common and similar clinical manifestations in oral cavity and diagnosis based on histological changes of the tissues after biopsy and immunofluorescence is necessary.

Desquamative gingivitis (DG) is a clinical condition with unclear etiology. This is not a specific diagnosis but a descriptive term for nonspecific gingival manifestation which is associated with different diseases. A variety of mucocutaneous disorders represent gingival manifestations in the form of desquamative lesions or ulceration of the gingival (1,

2, 3, 4, 5). The most important diseases are: lichen planus (Fig. 18, 19, 20, 21, 22), cicatricial and bullous pemphigoid, pemphigus vulgaris (Fig. 1, 2, 3, 4, 5, 6, 7), erythema multiforme (Fig. 8,9,10) as well as allergic stomatitis, psoriasis vulgaris (Fig. 11, 12, 13, 14, 15, 16, 17). DG is spread over mainly women at middle and advanced age (2, 4). Significant subjective sensations are: warmth, tenseness, tingling, itchiness, burning, and pain. Erythema and oedema of the marginal and attached gingiva are clinically observed predominantly in the frontal areas (2, 3, 4). Typical sign is desquamation of the epithelium with painfull erosive lesions and formation of hemorrhagic bulls by pressing. Identification of the main disease has been based of the following criteria: detailed clinical examination of the buccal and extrabuccal lesions, biopsy for pahtoanatomical examination, examination with direct immunofluorescence and with indirect immunofluorescence of the serum (1, 2, 4, 5).

### CASE 1:

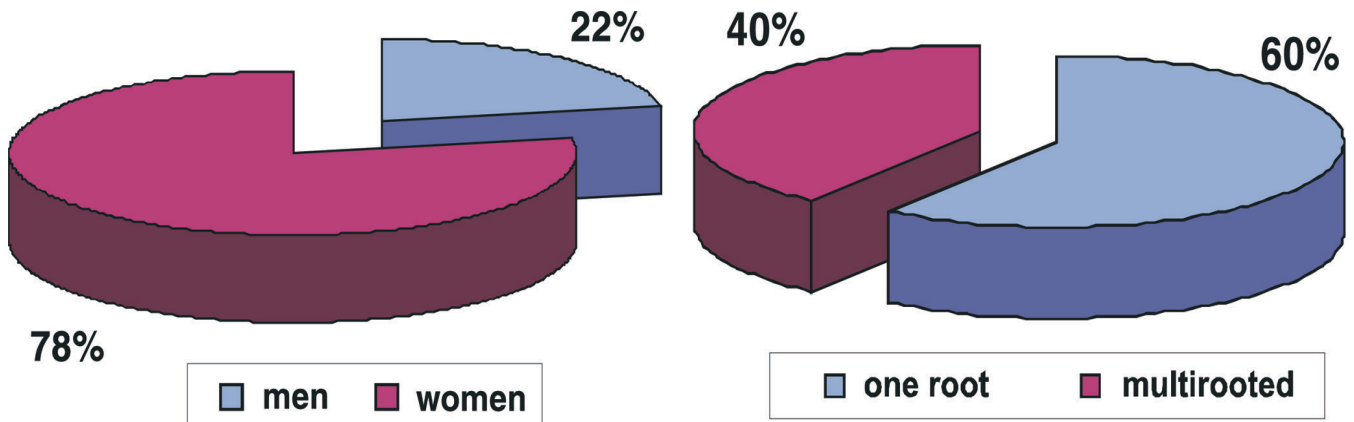
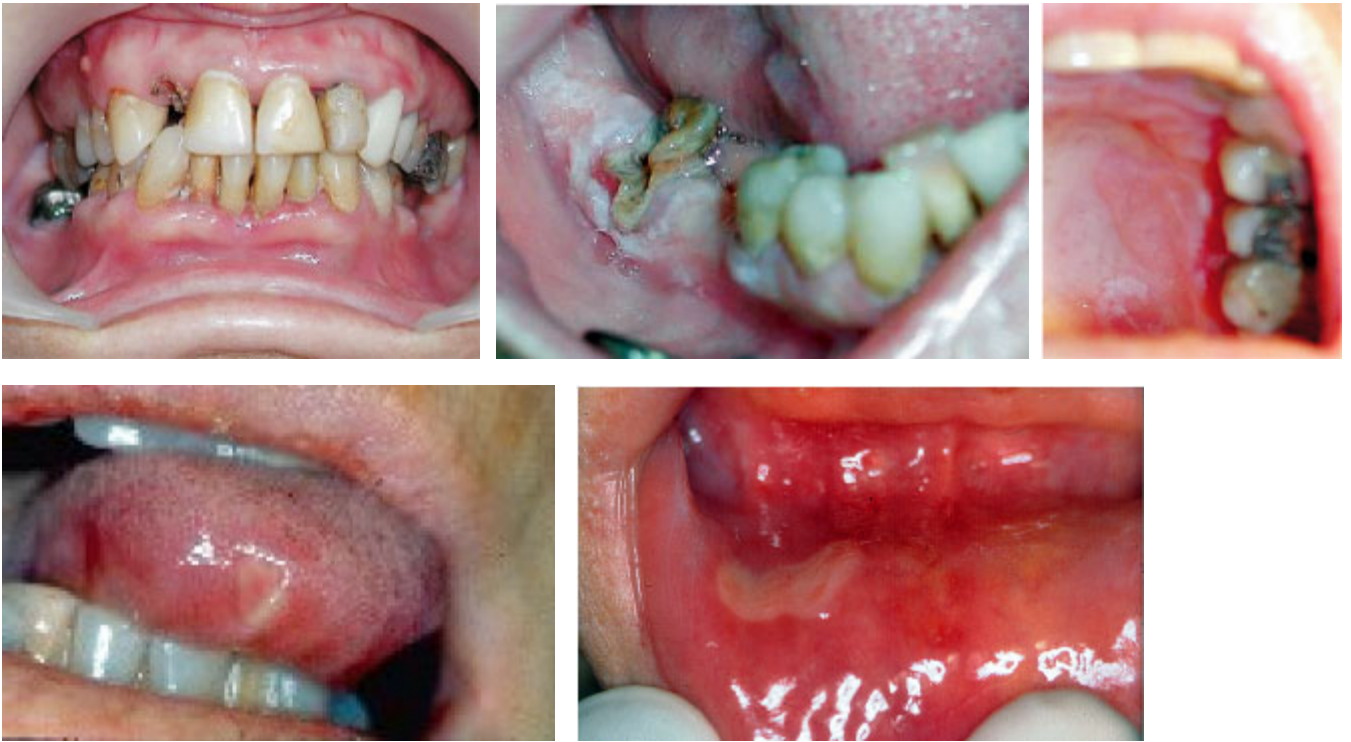

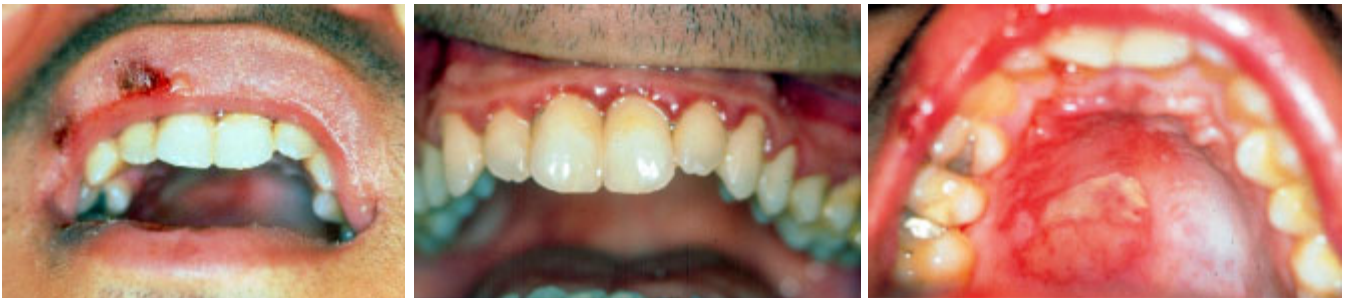Fig. 1, 2 – Pemphigus vulgaris in 82 years old man.

**CASE 2:**



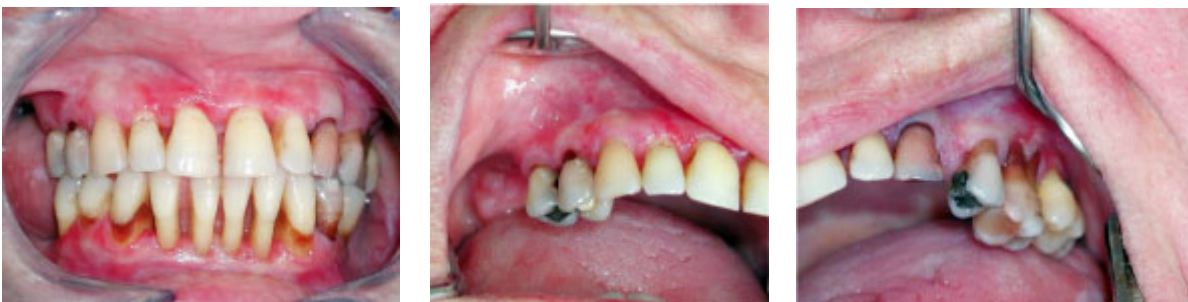**Fig. 3, 4, 5, 6, 7** – Oral lesions of pemphigus vulgaris in 56 years old woman.

**CASE 3:**



**Fig. 8,9,10** – Erythema multiforme in 24 years old man after systemic administration of nonsteroid anti-inflammatory drug.

**CASE 4:**



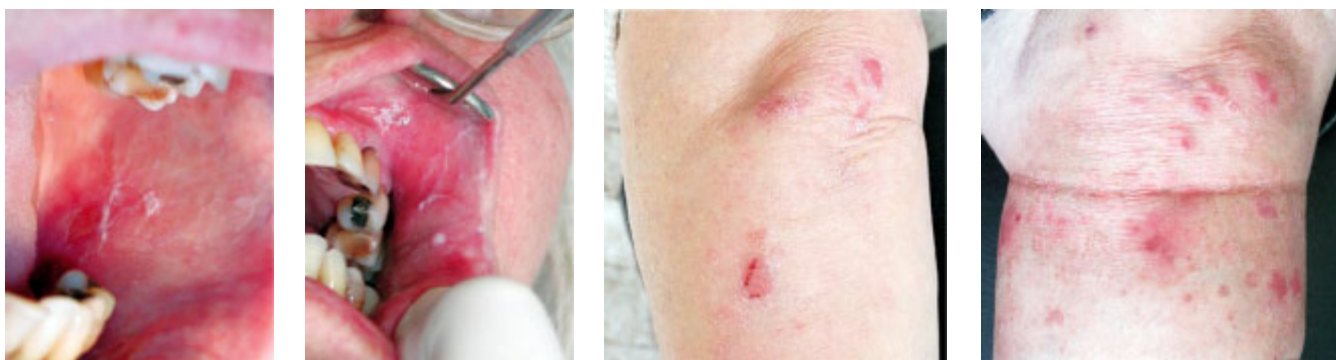

Fig. 11, 12, 13, 14, 15, 16, 17 – Oral and cutaneous manifestations of psoriasis vulgaris in 68 years old woman.

**CASE 5:**

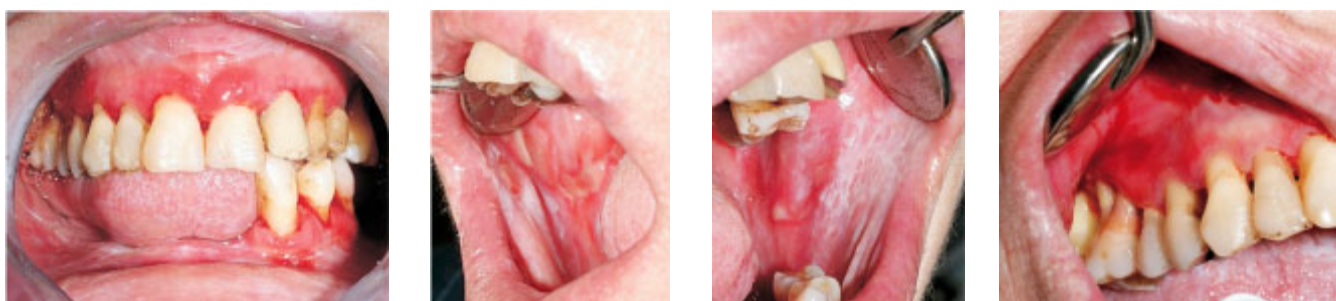
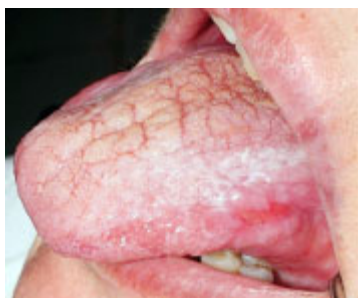
Fig. 18, 19, 20, 21, 22 – Oral lesions in woman with erosive lichen planus.



**CONCLUSION:**

The variety of the clinical characteristics of the presented diseases with a manifestation of desquamative gingivitis shows the necessity of an exact diagnosis to assure an adequate treatment.

**REFERENCES:**

1. Langlais RP, Miller CS. Color atlas of common oral diseases. Second edition 1998 Williams @ Wilkins, USA, 203p.
2. Laskaris G. Atlas des maladies buccales. 1994, Georg Thieme Verlag, Stuttgart, Germany, Flammarion, 370p.
3. Newman MG, Takei HH, Carranza FA. Carranza's clinical periodontology. Copyright 2002, ninth edition, Philadelphia, W.B. Saunders Company.
4. Pindborg JJ. Atlas des maladies de la muqueuse buccale. 1994, Masson, Paris, 397p.
5. Plemons JM, Gonzales TS, Burkhatr NW. Vesiculobillous diseases of the oral cavity. Periodontology 2000, 1999; 21: 158-175.

**Address for correspondence:**

Christina Popova, PhD, DM  
 Department of Periodontology,  
 Faculty of Dental Medicine, Medical University - Sofia  
 1, Georgi Sofiiski str., 1431 Sofia, Bulgaria  
 e-mail: hrpopova@yahoo.com;  
 Velitchka Doseva - vdoseva@yahoo.com  
 Kamen Kotsilkov - kotsilkov@mail.bg