

A CURRENT 4-YEARS RETROSPECTIVE SURVEY OF 64 SURGICALLY TREATED ZYGOMA COMPLEX FRACTURES IN DEPARTMENT OF MAXILLO-FACIAL SURGERY, UNIVERSITY HOSPITAL 'ST. ANNA', SOFIA

Elitsa G. Deliverska, Martin Rubiev.

Department of Oral and Maxillofacial surgery , Faculty of Dental Medicine, Medical University, Sofia, Bulgaria.

ABSTRACT:

Purpose: The goal of this material was to be an example of the complications that can occur in cases of zygoma fractures and to draw the attention of the clinicians to the need of accurate diagnose and early treatment of the associated with zygoma fractures traumas.

Materials and methods: Medical records of 276 patients with different traumas in face and neck area treated in our department were reviewed. Of those 64 suffered from zygoma fractures and they were classified according to age, sex, cause of trauma, presence or absence of associated trauma, etc.

Results: As other studies also show, we determined that the most common cause of injury was assault and road accidents, followed by sport, industrial, etc. Males between 20 and 40 years old were the biggest group of patients, often after alcohol consumption.

Associated traumas occurred more frequently in cases of motor vehicle accident than in other cases and were presented by closed head trauma, ophthalmologic problems, extremities fractures, etc.

Conclusion: Delayed treatment of zygoma injuries is feasible and yields in good results when the severity of trauma needs it, but early repair of such injuries prevent late complications and should be preferred when possible.

Key words: maxillofacial trauma, zygoma complex fractures

PURPOSE:

The aim of this retrospective study was to analyze the characteristics of zygoma complex fractures and evaluate treatment results.

MATERIALS AND METHODS:

A retrospective review of zygoma fractures presenting to department of Maxillofacial surgery, University hospital 'St. Anna', Sofia the between 2005 and 2009 was performed.

Demographics, associated injuries, computed tomographic scan findings, management, treatment and follow-up were collected. The following parameters were evaluated: age, sex, cause of accident, location and type of fractures, presence and location of associated injuries, computed tomographic scan findings, management, treatment methods and complications.

RESULTS:

In Department of Maxillofacial surgery 'St. Anna' were treated 276 patients with trauma. 64 (23,2%) of them were with zygoma complex fractures. The ratio of male to female was 49 male / 15 female.(fig. 1)

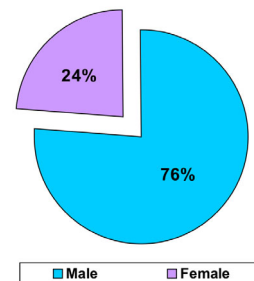


Fig. 1. Distribution according to gender

Patients between 20-40 years old were the major group- 59,4% (38 patients) followed by 40-60 years-26,6% (17 patients) and 60-80 years 14% (9).

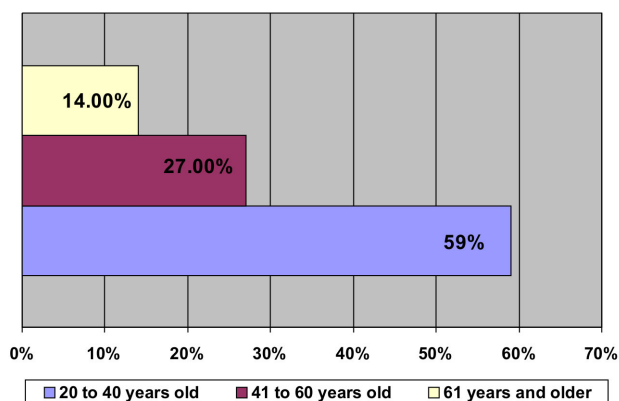


Fig. 2. Distribution according to age

Assault was the most common cause of injury 37,5% (24 patients) followed by motor vehicle accident 31,3% (20), fall 20,3% (13), sports 6,2%(4), industrial accidents 3,1% (2), gunshot (1). 26 patients were examined by computed tomography (CT) scans before operation.

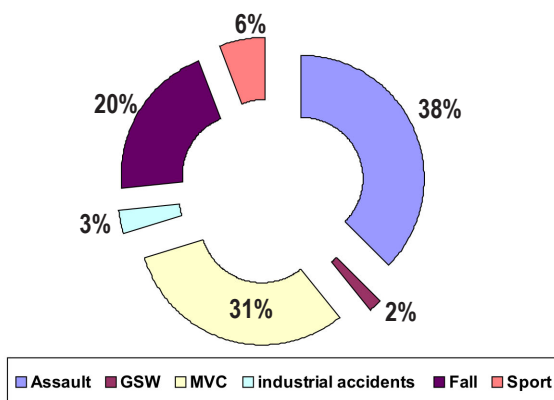


Fig. 3. Analysis according to mechanism of trauma

Associated injuries occurred in 57,8% (37 patients). Serious ocular injury occurred in 4 patients and 20 others had transitory diplopia. There were patients with associated closed head trauma with documented loss of consciousness (25), orthopedic trauma (7), skull fracture and intracranial injury (1). Associated cervical-spine fractures were not found. (fig.4)

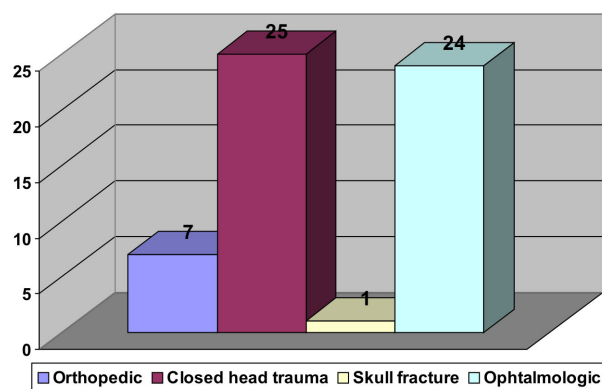


Fig. 4. Distribution according to associated trauma type

DISCUSSION

As other studies also show, we determined that the most common cause of injury was assault- 37,5% followed by road accidents, sport, industrial, etc. Males between 20 and 40 years old- 59,4% were the biggest group of patients, often after alcohol consumption.

Associated traumas was observed in 57,8 % and occurred more frequently in cases of motor vehicle accident than in other cases and were presented by head trauma, followed by ophthalmologic problems, extremities fractures.

Motor vehicle accidents were also the leading cause of orbital floor fractures, followed by physical assault and sports-related mechanisms. Associated facial fractures were found in some patients and the most prevalent of which was the nasal bone fracture. The most common signs and symptoms associated with zygoma complex fractures were: facial deformities, enophthalmos, diplopia, compromised mouth opening if present, inflammation of the mucosa of the maxillary sinus, and above all incidence of sensory deficit in the distribution area of the infra-orbital nerves and the dental plexus, periorbital ecchymosis, subconjunctival hemorrhage

Most of the patients were examined by the ophthalmology service preoperatively and reviewed postoperatively as indicated. These injuries occur more often in patients with orbital blowout fractures compared with comminuted orbitozygomatic complex fractures or simple zygomatic fractures.

Ophthalmology consultation is recommended for all patients presenting with orbitozygomatic fractures, and is essential for patients with orbital blowout fractures, based on the high incidence of clinical ocular findings and injuries in this subgroup of patients. Forty-one of these patients were seen by an ophthalmologist as the initial consultant for ocular and orbital injuries recognized by the emergency staff. This survey reveals the lack of awareness in a regional

trauma center of certain ocular and periocular signs that may be indicative of more serious ocular injuries.

Enophthalmos and hypoglobus corrected in almost all patients. Correction of hypoglobus is technically easier than enophthalmos, because enophthalmic correction requires a wide, deep subperiosteal dissection and implant positioning, posterior to the equator of the globe, with the inherent risk of orbital apex injury.

Diplopia was resolved in 20 patients with preoperative impairment. Three patients suffered blindness.

Most of the patients were treated with three-point fixation (zygomatic arch, frontozygomatic suture, infraorbital rim) using a 1.3/2.0-mm osteosynthesis miniplates- and- screw titanium system, or two-point fixation (frontozygomatic suture, infraorbital rim).

19 patients had been operated via trans-oral access (Keen-Village method) and 21 patients with wire osteosynthesis and 6 patients with Ti miniplates-and-screw. 15 patients were with orbital floor fracture: 8 were treated with titanium mesh; 5 were treated with frozen cartilage graft and 2 with Ti mesh plus frozen cartilage graft. On the cases of zygoma complex fractures, combine with brain traumas

the specialize treatment of facial injuries was postponed until stabilization of brain status. Delayed repair of maxillofacial injuries in severely injured patients is feasible and yields in good results compared to early fracture repair.

CONCLUSIONS:

Maxillofacial trauma is without doubt still a very challenging area. Delayed repair of maxillofacial injuries in severely injured patients is feasible and yields in good results compared to early fracture repair. The treatment for ZCF should be selected according to the fracture types. The key of operation is to recover the malar prominence. Remodeling the length and radian of zygomatic arch guarantee the recovery of malar prominence. Zygomatic-sphenoid and zygomatic-maxillary fissures are very important reference marks for reduction and fixation.

Orbital floor blowout fractures have a high incidence of muscle entrapment that must be recognized and treated early to avoid muscle necrosis and permanent ocular restriction from fibrosis. Medial orbital wall fractures with entrapment are rare, but early recognition and operative release of the entrapped muscles result in better outcomes.

REFERENCES:

1. Barry C, Coyle M, Idrees Z, Dwyer MH, Kearns G. Ocular findings in patients with orbitozygomatic complex fractures: a retrospective study. *J Oral Maxillofac Surg.* 2008 May; 66(5):888-92. [PubMed] [CrossRef]
2. He DM, Zhang Y, Zhang ZK. [A study on the classification and treatment of zygomatic complex fractures] [in Chinese] *Zhonghua Kou Qiang Yi Xue Za Zhi.* 2004 May;39(3):211-3; discussion 213. [PubMed]
3. Losee JE, Afifi A, Jiang S, Smith D, Chao MT, Vecchione L, et al. Deleyiannis FW. Pediatric orbital fractures: classification, management, and early follow-up. *Plast Reconstr Surg.* 2008 Sep;122(3):886-97. [PubMed] [CrossRef]
4. Nardi P, Acocella A, Acocella G. Sequelae of zygomatic-orbito-maxillary fractures. Report of 70 cases and review of literature. [in Italian] *Minerva Stomatol.* 2003 Jun; 52(6): 261-6. [PubMed]
5. Rohner D, Tay A, Meng CS, Hutmacher DW, Hammer B. The sphenozygomatic suture as a key site for osteosynthesis of the orbitozygomatic complex in panfacial fractures: a biomechanical study in human cadavers based on clinical practice. *Plast Reconstr Surg.* 2002 Nov;110(6):1463-71; discussion 1472-5. [PubMed]
6. Tong L, Bauer RJ, Buchman SR. A current 10-year retrospective survey of 199 surgically treated orbital floor fractures in a nonurban tertiary care centre. *Plast Reconstr Surg.* 2001 Sep 1;108(3):612-21. [PubMed]
7. Villarreal PM, Monje F, Morillo AJ, Junquera LM, Gonzalez C, Barbon JJ. Porous polyethylene implants in orbital floor reconstruction. *Plast Reconstr Surg.* 2002 Mar;109(3):877-85; discussion 886-7. [PubMed]

Corresponding author:

Elitsa Georgieva Deliverska,
Department of Oral and Maxillofacial Surgery, Faculty of Dental Medicine, Medical University - Sofia,
1, St. Georgi Sofiiski boul., 1431 Sofia, Bulgaria
E-mail: elitsadeliverska@yahoo.com,